


## Case report

## The Role of Tocilizumab in Treatment of a Patient with COVID-19: a Case Report

Parviz Amri Maleh<sup>1</sup>, Kayvan Latifi<sup>2</sup>, Shahram Seyfi<sup>1</sup>, Khadijeh Ezoji<sup>3\*</sup> 

### Abstract

SARS-CoV-2 (COVID-19) is an infectious disease caused by a new discovered Coronavirus. Most people infected with the COVID-19 virus recover without special treatment and experience mild to moderate respiratory disease. In the elderly and people with underlying diseases such as cardiovascular disease, diabetes, chronic respiratory disease and cancer, there is a higher risk of developing the severe form of the disease. So far, no specific drug has been found to prevent or treat COVID-19. A 52-years old diabetic man with COVID-19 was admitted to Ayatollah Rouhani Hospital Babol, Iran. After 12 days of hospitalization and treatment, with respiratory distress and oxygen saturation level to 60%, he was transferred to the intensive care unit. After receiving a 400 mg dose of actemra or tocilizumab, the patient became severely dehydrated and the oxygen saturation level reached over 90% within a few hours, and 8 days after receiving tocilizumab (TCZ; actemra), the patient was suffering from complications of pneumonia. So far, there have been reports of improvement in patients with Coronavirus (COVID-19) with severe actemra or tocilizumab. Typically the COVID-19 virus appears to be able to be cause the over-immune reaction and typically the cytokine storm, which often includes IL-6, therefor may be IL-6 antagonist improves patients's condition.

**Keywords:** COVID-19; Actemra; Tocilizumab

1. **Clinical Research Development Unit of Ayatollah Rouhani Hospital, Babol University of Medical Sciences, Babol, Iran**
2. Specialty student of Critical Care Medicine, Department of Anesthesiology, School of Medicine, Babol University of Medical Sciences
3. Social Determinants of Health Research Center, Health Research Institute, Babol University of Medical Sciences, Babol, Iran

**Corresponding Author:**

Khadijeh Ezoji, MD; Social Determinants of Health Research Center, Health Research Institute, Babol University of Medical Sciences, Babol, Iran; Tel: (+98) 911-1958480. Email: [dr.kh.ezoji@gmail.com](mailto:dr.kh.ezoji@gmail.com)

**Please cite this article as:** Amri Maleh P, Latifi K, Seyfi S, Ezoji K. The Role of Tocilizumab in Treatment of a Patient with COVID-19: a Case Report. *J Cell Mol Anesth.* 2020;5(2):117-21.

### Introduction

A number of unexplained cases of pneumonia were reported in Wuhan, Hubei Province, China, In December 2019. On January 12, 2020, the World Health Organization named the virus 2019 novel corona virus 2; belonging to the Coronaviridae family. (1, 2). Coronaviridae is a family of single-stranded, enveloped and positive-sense RNA virus. In human,

Coronavirus can cause respiratory tract infection.

SARS-CoV-2 (COVID-19), Coronavirus Acute Respiratory Syndrome (SARS-CoV) and Coronavirus Middle East Respiratory Syndrome (MERS-CoV)) are members of the coronavirus family that can infect humans and SARS-CoV-2 is the seventh member of this family (3).

The fever, cough, and fatigue were the most common symptoms in patients with COVID-19. A

relatively small percentage of involving patients were asymptomatic.

Quantitative reverse transcriptase polymerase chain reaction (RT-PCR) to detect the SARS-CoV-2 nucleic acid is the primary and most important method for diagnosis (4). Most patients showed normal leukocytes, lymphopenia, increased C-reactive protein (CRP) and Erythrocyte sedimentation rate (ESR). Bilateral lung involvement was common (5).

For some patients with the new SARS-CoV-2 (COVID-19), their immune system is stimulated and launches a comprehensive attack known as the Cytokine storm. This over-reaction of the immune system can damage the tissue and cause the patient to die (6).

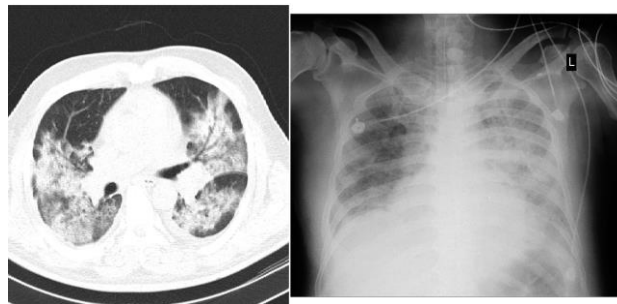
Tocilizumab (TCZ; Actemra) is a drug approved for the treatment of rheumatoid arthritis and young rheumatoid arthritis. It blocks the interleukin 6 cell receptor, cytokine, which can cause dangerous inflammatory waterfalls (7). There are reports of the use of tocilizumab as an effective treatment option in patients with COVID-19 (8, 9).

In this report, the experience of treatment with tocilizumab will be expressed in a corona patient.

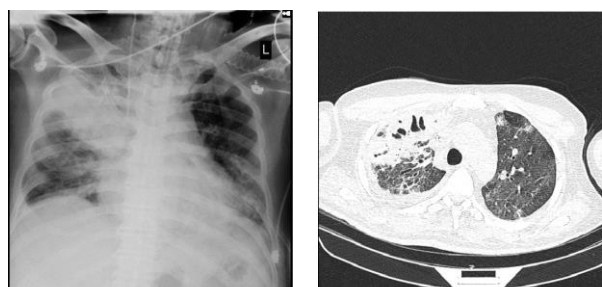
## Case Report

A 52-year-old diabetic patient with controlled blood sugar metformin was admitted to rohani Babol Hospital with fever, sweating, shortness of breath, and cough. After CT scan of the lungs and multiple lesions of ground-glass opacities, he was hospitalized with corona diagnosis and the necessary samples were taken from the respiratory system to confirm COVID-19 disease for the patient (Figure 1). The patient's oxygen saturation level was 80% upon arrival. Patients underwent Tamiflu, Chloroquine, Lopinavir / Ritonavir (Kaletra) and Vancomycin, Levofloxacin and Ribavirin, oxygen therapy and other symptomatic treatment for 12 days.

On the twelfth day of hospitalization, the patient developed respiratory distress despite the above-mentioned treatments and with an oxygen level of 60%, it was transferred to the intensive care unit. The patient's condition at the time of entering ICU



**Figure 1.** Chest x-ray and chest CT scan before TCZ administration.



**Figure 2.** Chest x-ray and chest CT scan two weeks after TCZ administration.

was as discussed in the following lines.

For the patient, NIV (Non-invasive ventilation) was assigned with positive end-expiratory pressure (PEEP) = 8 and pressure support = 18 the next day, it was oxidized to 82% oxygen level and subjected to ACMV ventilation mode. After one day of invasive ventilation, the patient's oxygen saturation level was between 65 and 80 percent, so tocilizumab was injected with a 400 mg vial for the patient. Four hours after the injection of tocilizumab, the patient's oxygen saturation level reached 90% and then the patient recovered within a few days. The patient's tests were compared before and after receiving tocilizumab in Table 1.

On the eighth day after administration of tocilizumab, despite continued extensive antibiotic therapy, endotracheal tube secretion was increased and became purulent. The patient's tests also preferably included leukocytosis, neutrophil. There was also lobar pneumonia in the patient's chest and CT scan (Figure 2). *Acinetobacter* patient sensitive to colchicine was found in the sputum collection and the patient was treated.

**Table 1: Patient's laboratory results Before and after tocilizumab treatment**

	Before TCZ	After TCZ (2 week)
<b>WBC count×10<sup>9</sup></b>	7000	23900
<b>Neutrophil percent</b>	76	88.9
<b>Lymphocyte percent</b>	19,1200	5.3
<b>Platelet count×10<sup>9</sup></b>	266	280
<b>Hemoglobin, g/L</b>	125	96
<b>Creatinine, mmol/L</b>	1	0.8
<b>Blood Urea Nitrogen (BUN) mg/dL</b>	14	35
<b>Alanine Transaminase (ALT); U/L</b>	38	24
<b>Aspartate Transaminase (AST); U/L</b>	49	22
<b>Blood Sugar level (mg/dL)</b>	119	140
<b>Serum Creatin Phosphokinase (CPK) U/L</b>	188	105
<b>Prothrombin time (PT)</b>	12	15
<b>Activated Partial Thromboplastin Time (aPTT)</b>	31	32
<b>International Normalized Ratio (INR)</b>	1	1.4
<b>Lactate dehydrogenase, U/L</b>	663	571
<b>C-reactive protein, mg/L</b>	91	121
<b>Erythrocyte Sedimentation Rate (ESR)</b>	45	-
<b>Serum level of Sodium ion</b>	132	135
<b>Serum level of Potassium ion</b>	3.9	4.7
<b>Serum level of Magnesium ion</b>	1.9	2.5
<b>Serum level of Pro-calcitonin (ng/mL)</b>	-	0.9

On the 19th day, the patient was hospitalized and treated in the intensive care unit with partial

respiratory recovery and underwent non-invasive adjuvant ventilation for five days and was discharged

from the ICU with an oxygen saturation level above 92% in room air without respiratory distress and shortness of breath.

## Discussion

In this study, the therapeutic effect of a dose of TCZ in a critically ill patient with COVID-19 and its complications has been reported. In this patient, the level of acute phase reactors decreased and the patient gradually reached a stable state with a gradual decrease in interleukin 6 after TCZ administration.

The logical reason for the effect of TCZ in patients with COVID-19 is based on the role of interleukin 6 in this disease (6).

In a study about immunopathology of COVID-19 suggested that the pathogenic GM-CSF<sup>+</sup> Th1 cells and inflammatory CD14<sup>+</sup> CD16<sup>+</sup> monocytes caused excessive activated immune response and this response was linked to severe lung pathology in COVID-19 and It has been suggested that a monoclonal antibody targeting the IL-6 receptor may be effective in treating coronavirus pneumonia (12).

The effect a dose of TCZ seen in this patient was also seen in seriously ill patients with about 10 times elevated IL-6, and patients with higher level of IL-6 benefited from repeated TCZ treatment and a single dose of TCZ, despite concomitant use of glucocorticoids, failed in patients with critical illness (8).

However, complications of pneumonia were seen in this patient, and the patient underwent treatment for this complication in accordance with the collection of secretions. However, an increased risk of infections has been reported in tocilizumab. In a meta-analysis, patients with rheumatoid arthritis who underwent monotherapy with the tocilizumab had at least one more infection than the control group and having at least one serious infection in these patients did not have a statistically significant difference (10).

Other side effects have been reported in the tocilizumab, such as medication-related osteonecrosis of the jaw in patients with rheumatoid arthritis under treatment tocilizumab alone (11) or an increase in some laboratory markers such as lipids and liver function test and a decrease in the number of neutrophils in the blood test of these patients. There was no significant increase in the incidence of

malignancy, tuberculosis, or hepatitis associated with the use of tocilizumab (10), which was not observed in our patient requiring a longer test check than receiving the tocilizumab.

## Conclusion

In conclusion, the present study suggested that tocilizumab can be beneficial for critically ill patient with COVID-19, but should also consider the side effects of the drug.

## Acknowledgment

We would like to thank the medical staff of the Ayatollah Rouhani Hospital, Babol, Mazandaran for their efforts to help these patients.

## Conflicts of Interest

The authors declare that there are no conflicts of interest.

## References

1. Xu X, Chen P, Wang J, Feng J, Zhou H, Li X, et al. Evolution of the novel coronavirus from the ongoing Wuhan outbreak and modeling of its spike protein for risk of human transmission. *Science China Life sciences*. 2020;63(3):457-60.
2. Organization WHO. Clinical management of severe acute respiratory infection (SARI) when COVID-19 disease is suspected: interim guidance, 13 March 2020. World Health Organization, 2020.
3. Yang P, Wang X. COVID-19: a new challenge for human beings. *Cell Mol Immunol*. 2020;17(5):555-7.
4. Udugama B, Kadhiresan P, Kozlowski HN, Malekjahani A, Osborne M, Li VYC, et al. Diagnosing COVID-19: The Disease and Tools for Detection. *ACS Nano*. 2020;14(4):3822-35.
5. Shen B, Yi X, Sun Y, Bi X, Du J, Zhang C, et al. Proteomic and Metabolomic Characterization of COVID-19 Patient Sera. *Cell*. 2020.
6. Ye Q, Wang B, Mao J. Cytokine Storm in COVID-19 and Treatment. *Journal of Infection*. 2020.
7. Alten R. Tocilizumab: a novel humanized anti-interleukin 6 receptor antibody for the treatment of patients with rheumatoid arthritis. *Ther Adv Musculoskelet Dis*. 2011;3(3):133-49.
8. Luo P, Liu Y, Qiu L, Liu X, Liu D, Li J. Tocilizumab treatment in COVID-19: A single center experience. *J Med Virol*.

2020;92(7):814-8.

9. Zhang X, Song K, Tong F, Fei M, Guo H, Lu Z, et al. First case of COVID-19 in a patient with multiple myeloma successfully treated with tocilizumab. *Blood Adv.* 2020;4(7):1307-10.

10. Campbell L, Chen C, Bhagat SS, Parker RA, Östör AJ. Risk of adverse events including serious infections in rheumatoid arthritis patients treated with tocilizumab: a systematic literature review and meta-analysis of randomized controlled trials. *Rheumatology (Oxford)*. 2011;50(3):552-62.

11. Bennardo F, Buffone C, Giudice A. New therapeutic opportunities for COVID-19 patients with Tocilizumab: Possible correlation of interleukin-6 receptor inhibitors with osteonecrosis of the jaws. *Oral Oncol.* 2020;106:104659.

12. Zhou Y, Fu B, Zheng X, et al. Pathogenic T cells and inflammatory monocytes incite inflammatory storm in severe COVID-19 patients [published online ahead of print 13 March 2020]. *Natl Sci Rev.*